

# Rare Male DCIS

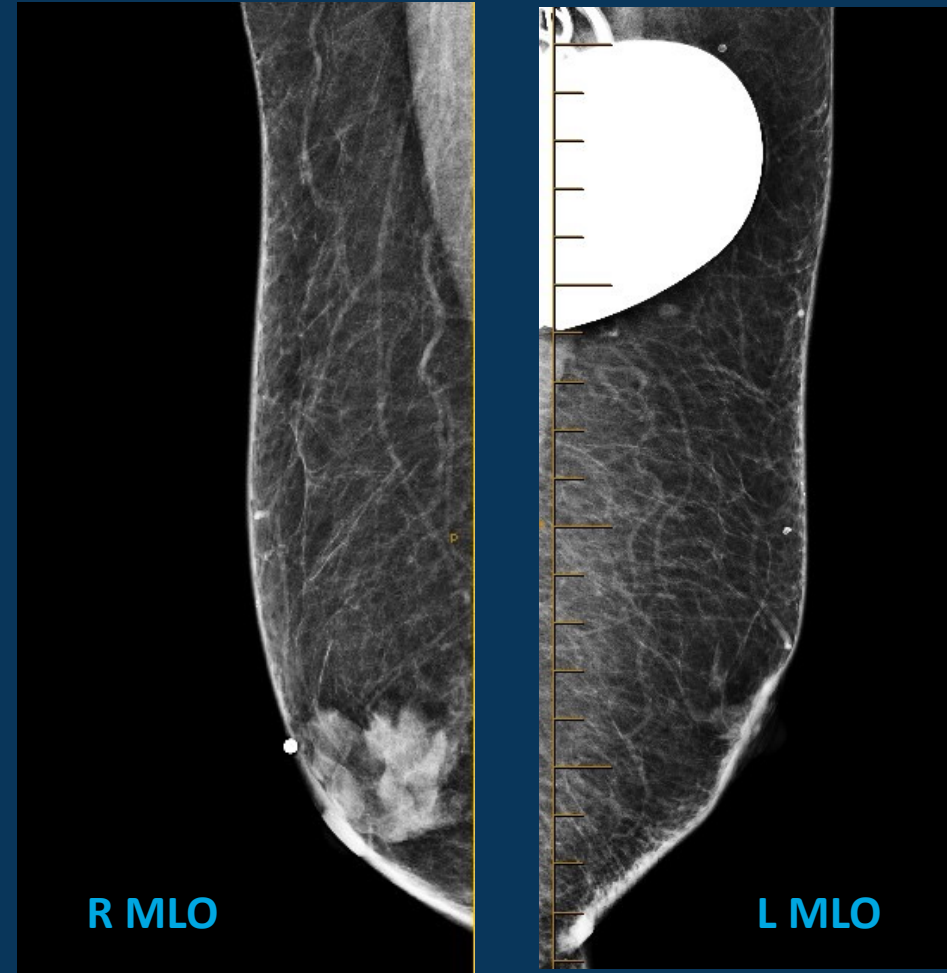
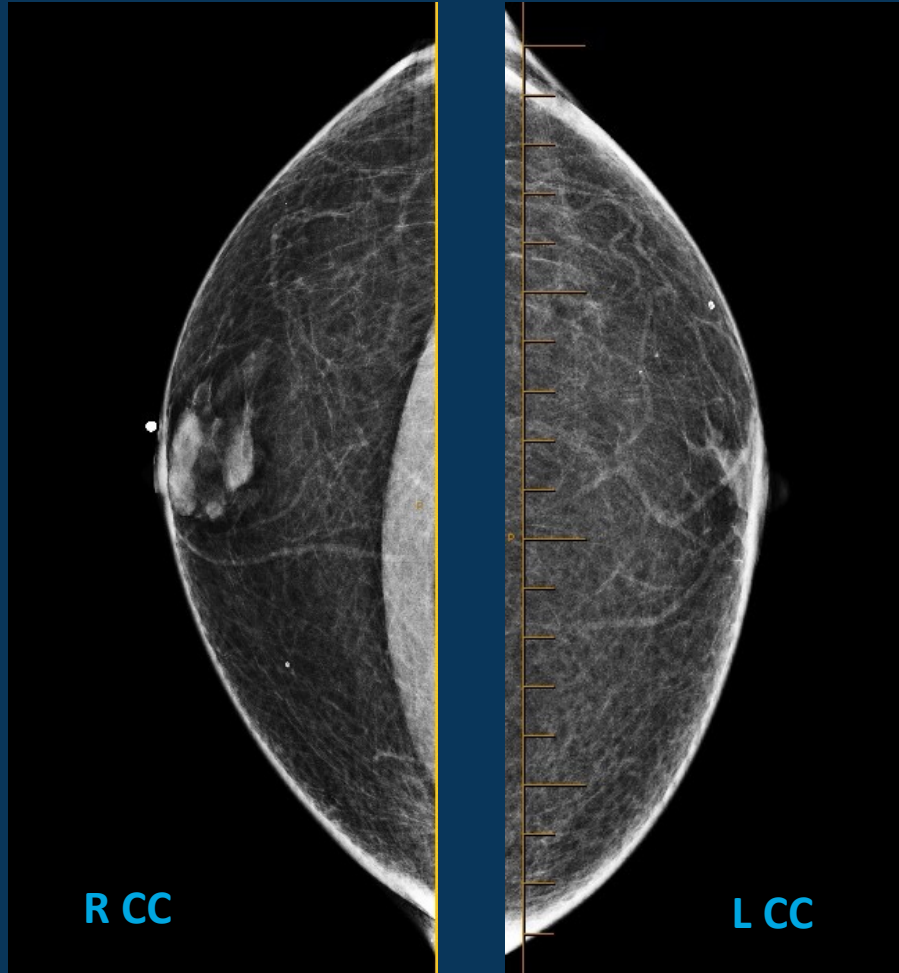
---

**CLINICAL VALUE**

*Elevate patient care and enhance value through  
innovation, collaboration and education*

 radiology partners®

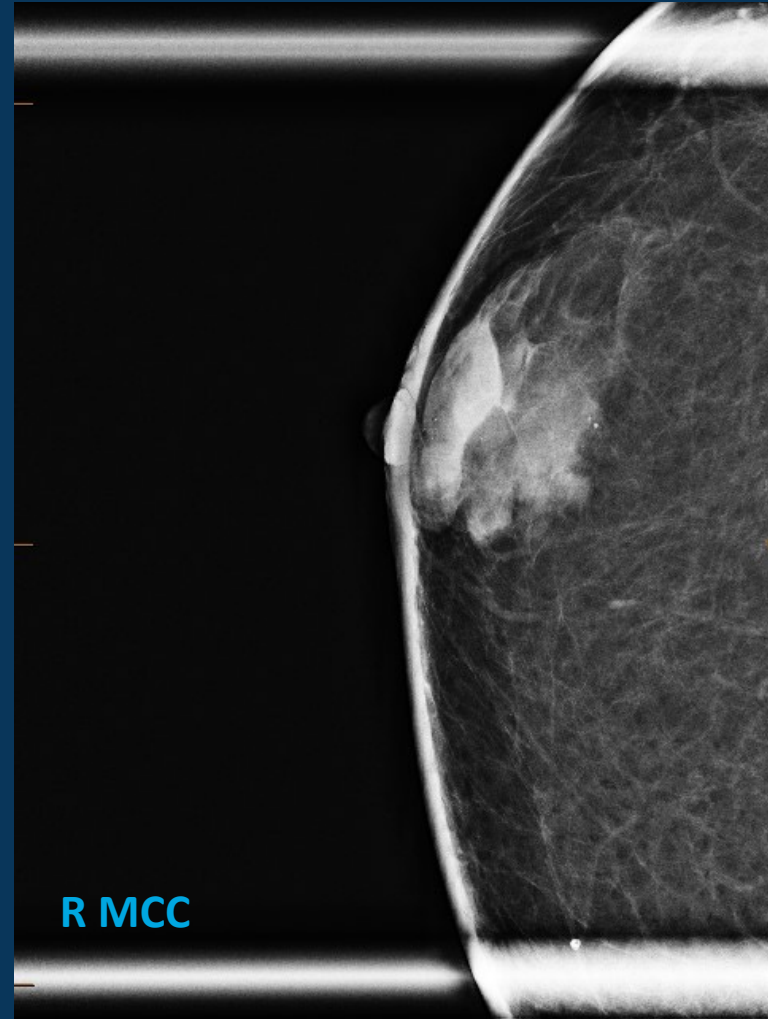
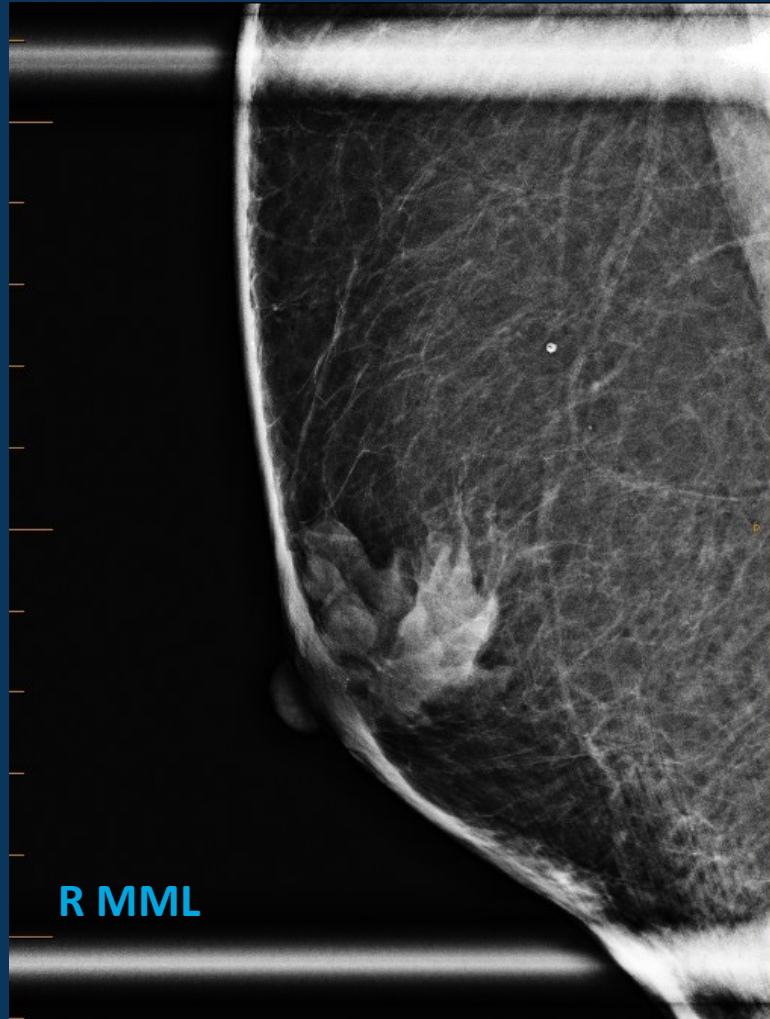# 77-year-old male with palpable area in the right breast



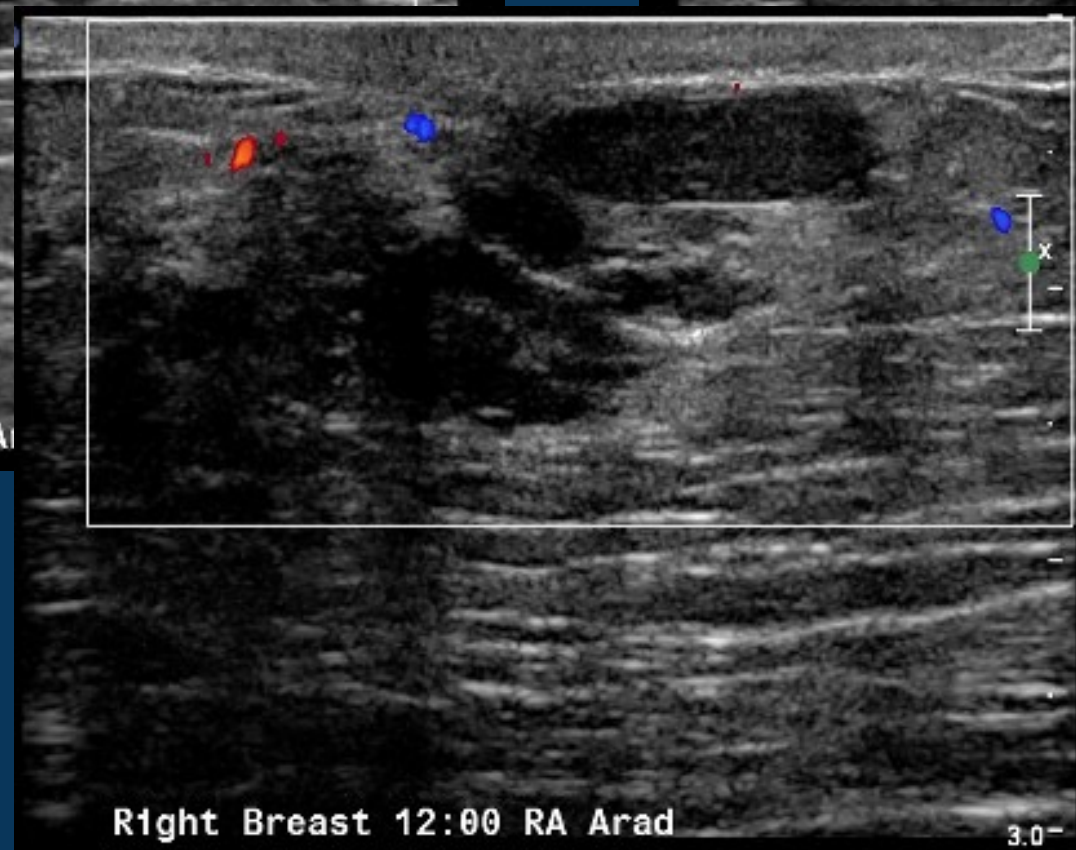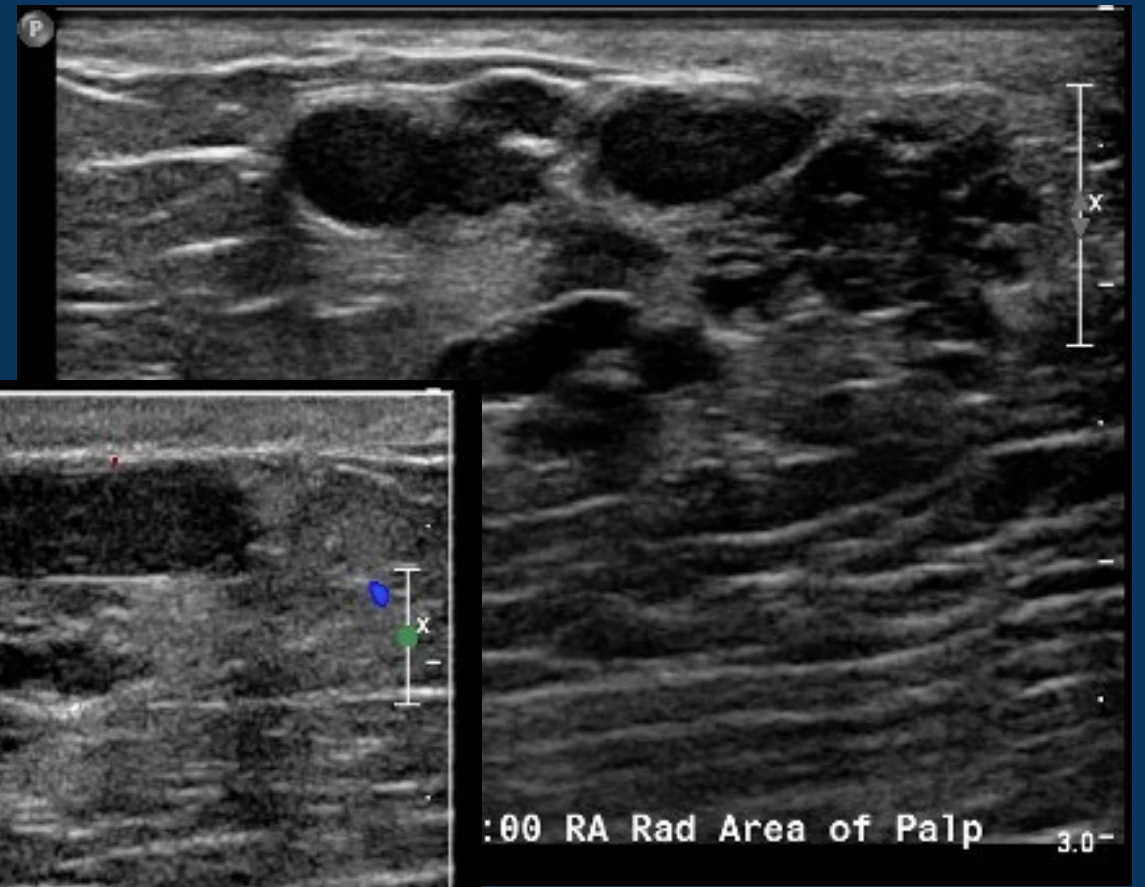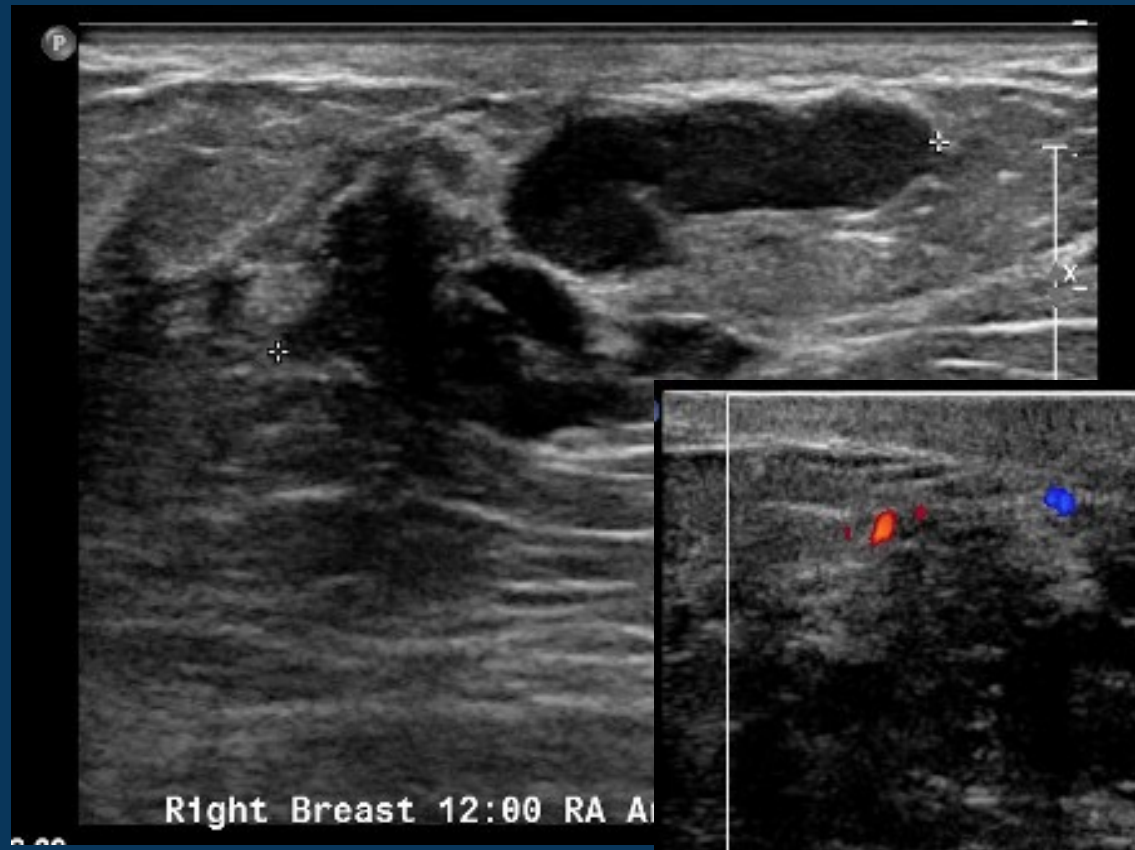
## CLINICAL VALUE

*Elevate patient care and enhance value through  
innovation, collaboration and education*

# Magnification views of palpable area in the right breast

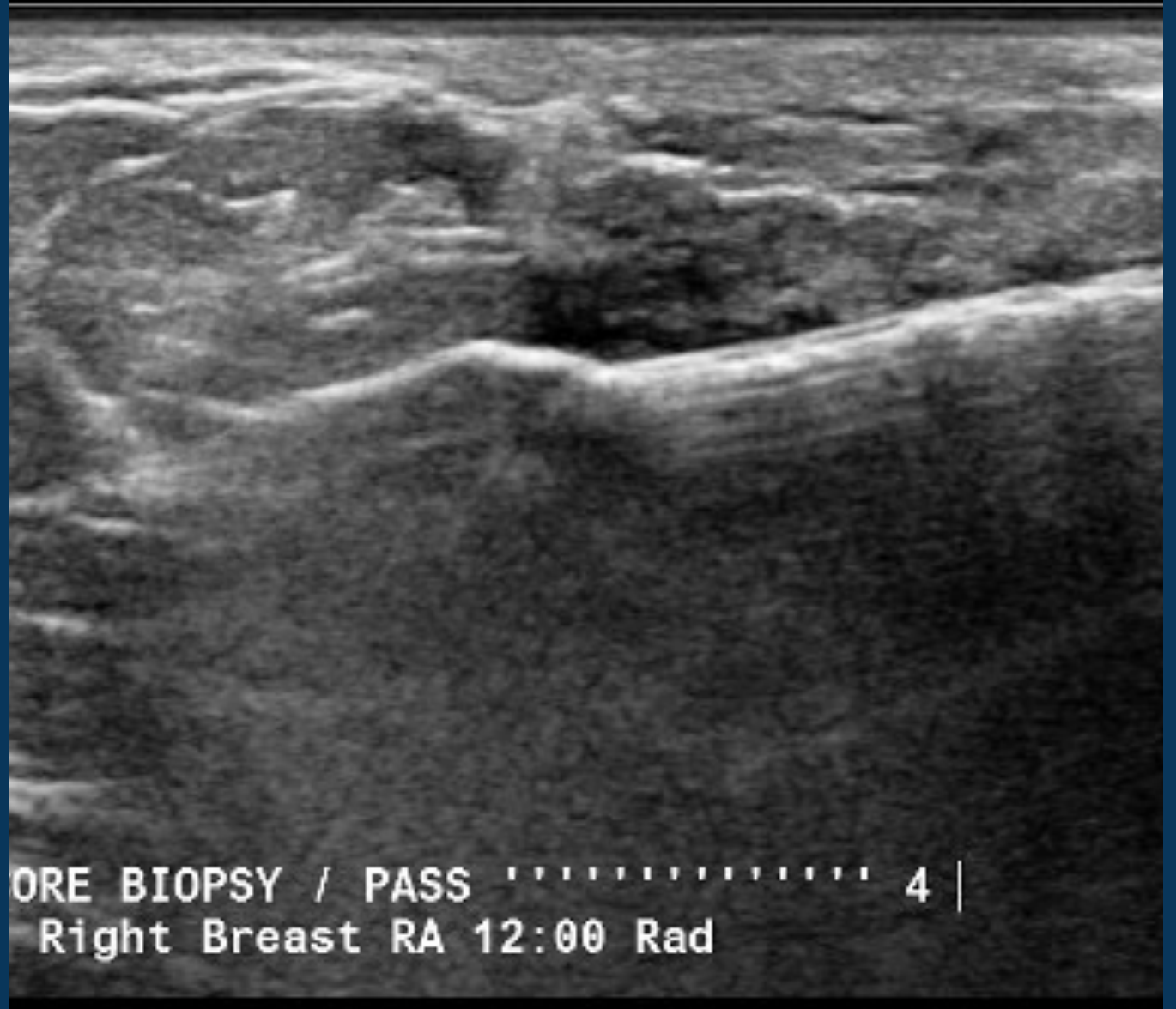

# Ultrasound images of palpable area in the right breast



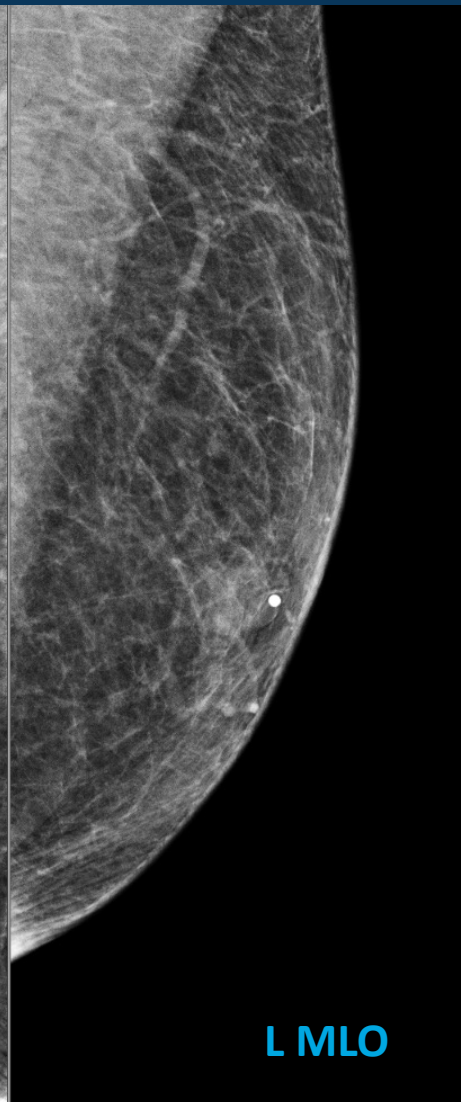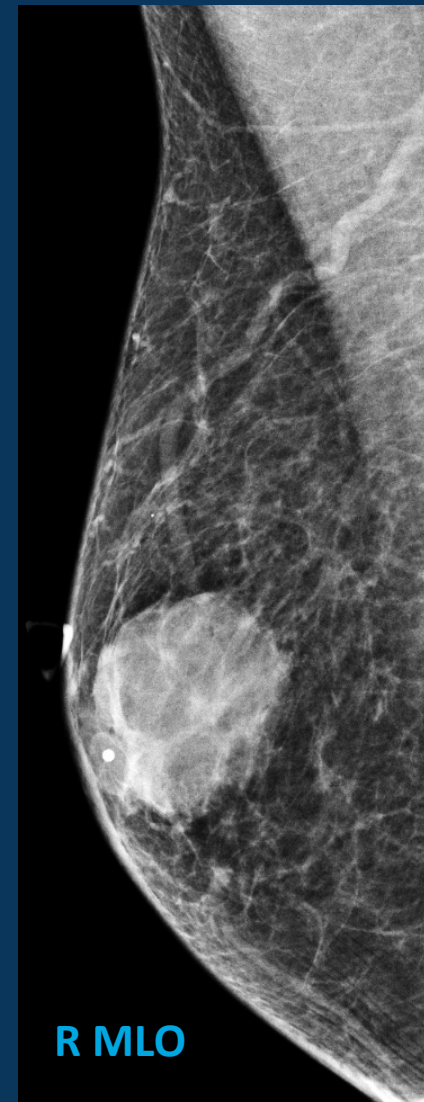
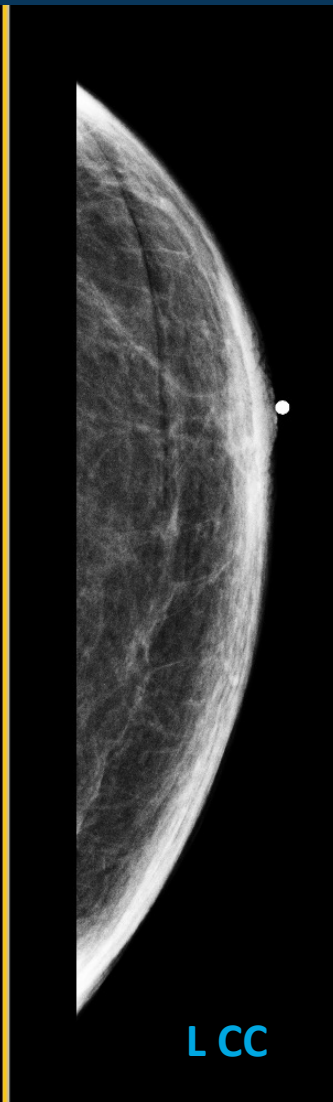
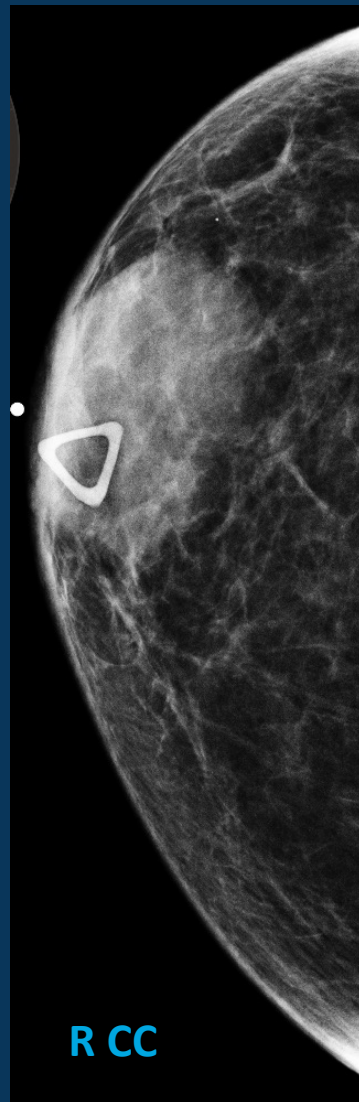
# Pathology:

Ductal carcinoma in situ,  
micropapillary type,  
intermediate grade. No  
invasive carcinoma  
identified.

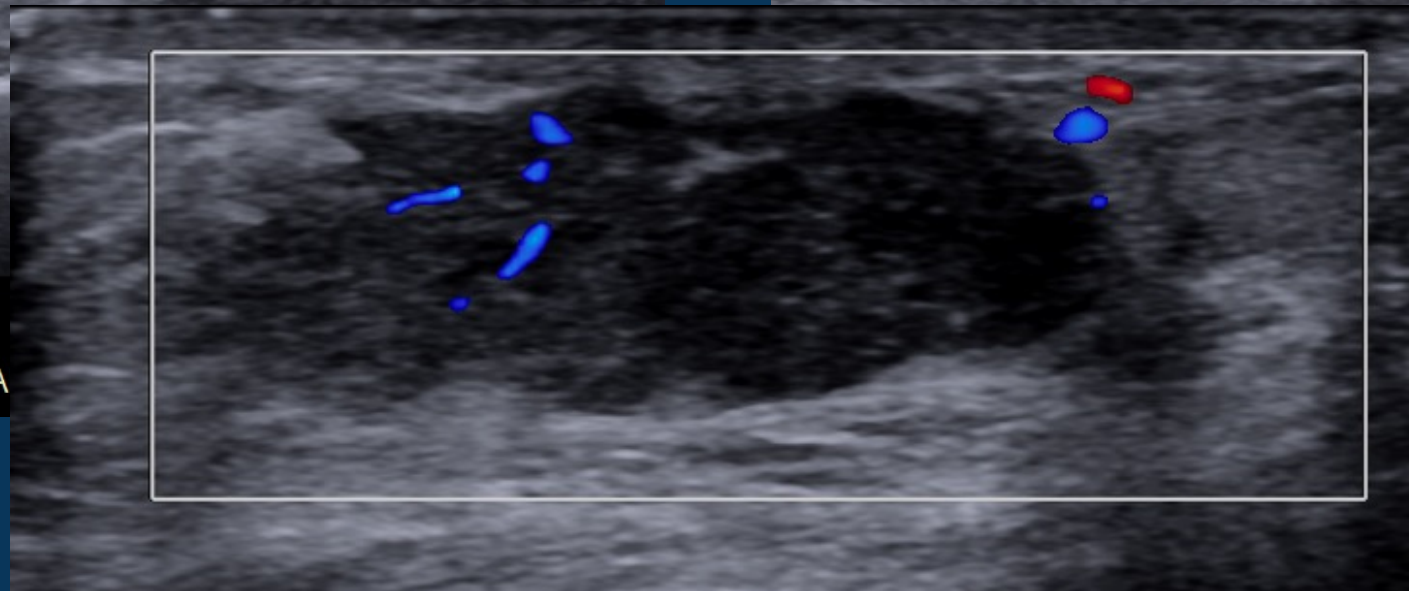
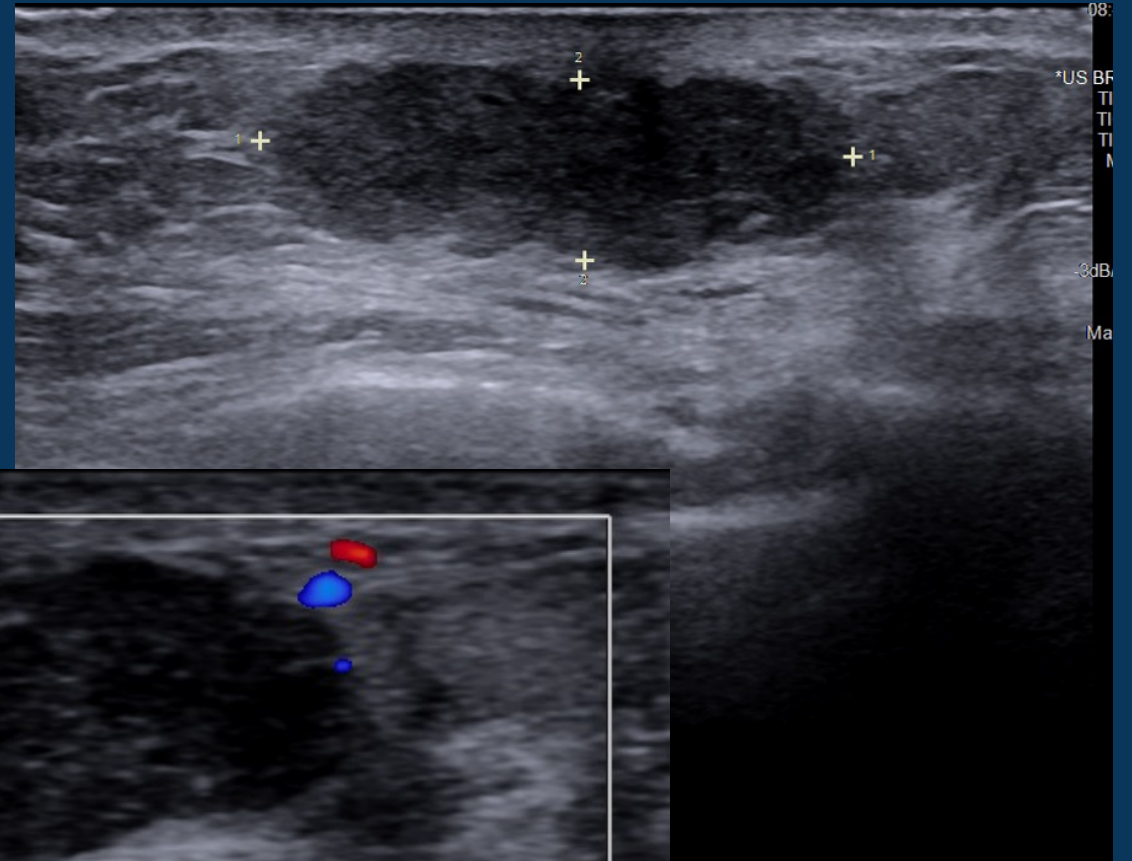
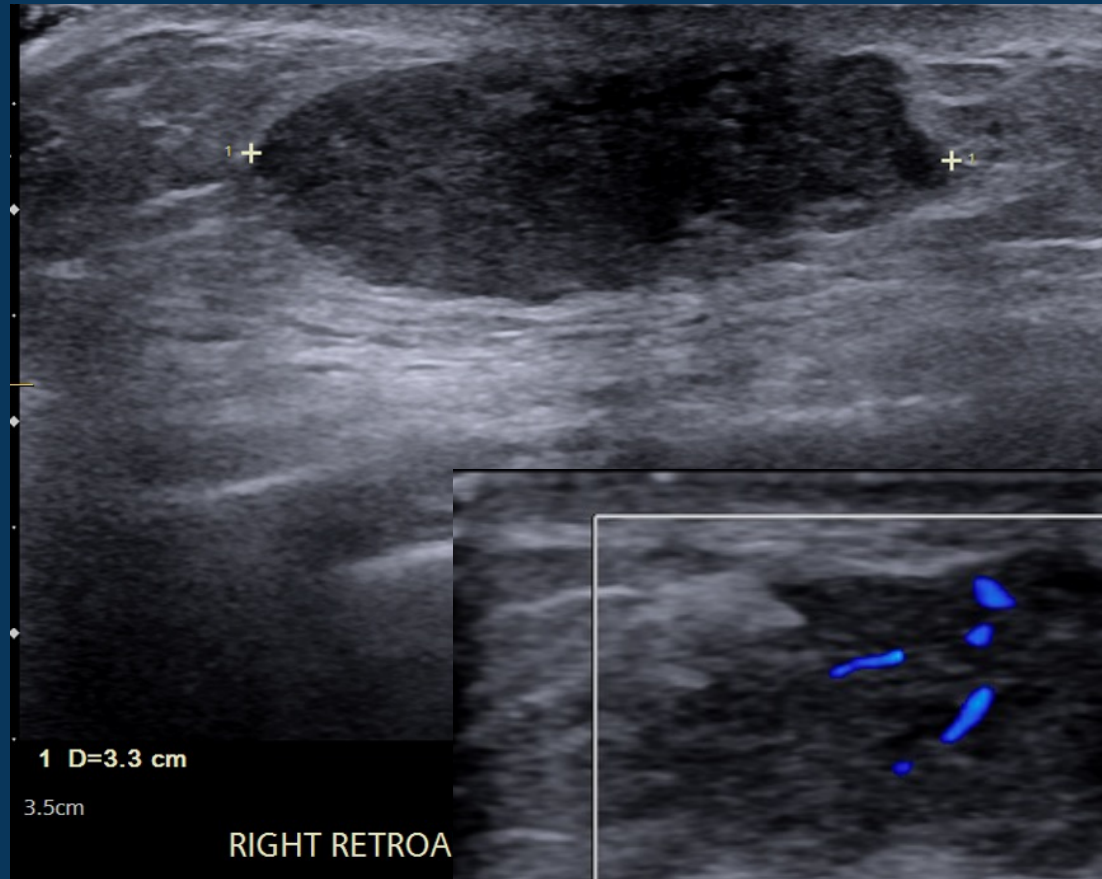


# Companion Case

73-year-old male who had recently undergone surgery for biliary cancer, presenting with a palpable right breast mass.



# Ultrasound images of palpable area in the right breast



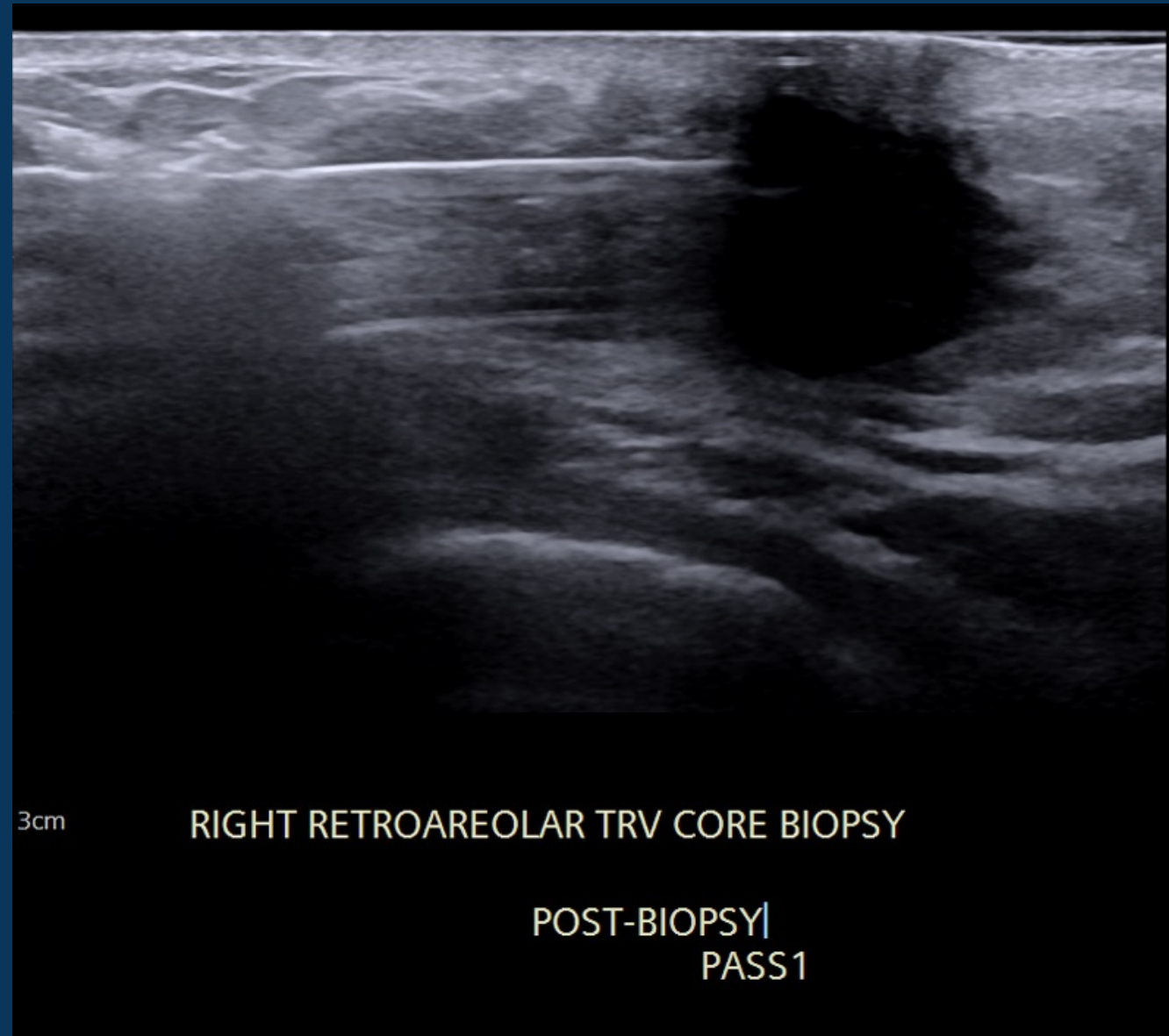


# DCIS in a male patient resembling gynecomastia

- Ductal carcinoma of the male is rare and is usually associated with invasive carcinoma.
- Gynecomastia is known to mask underlying breast calcifications and/or carcinoma.
- Ductal carcinoma in situ (DCIS) of the male breast represents approximately 0.1% of all breast cancers and less than 0.1% of all cancers in men.
- Most common presenting sign is a painless mass, but there may be breast pain, nipple discharge, or nipple retraction. Given the anatomy of the male breast, the lesions are usually central and slightly eccentric to the nipple, thus nipple involvement is relatively more common.
- Screening mammography indicates that calcifications are less frequently associated with male breast cancer as compared to female breast cancer. When present, these calcifications often have a benign or nonspecific appearance.

# Pathology:

Gynecomastia with florid pseudoangiomatic stromal hyperplasia



# References

- Brents M, Hancock J. Ductal Carcinoma In situ of the Male Breast. *Breast Care (Basel)*. 2016;11(4):288-290. doi:10.1159/000447768
- Fentiman I. Male breast cancer: A review. *ecancermedicalscience*. 2009;3:140
- Hittmair AP, Liningner RA, Tavassoli FA. Ductal carcinoma in situ (DCIS) in the male breast. A morphologic study of 84 cases of pure DCIS and 30 cases of DCIS associated with invasive carcinoma - a preliminary report. *Cancer*. 1998;83:2139–2149