

# Rad<sup>to</sup>Rad Learning

*Focused tips from our experts*

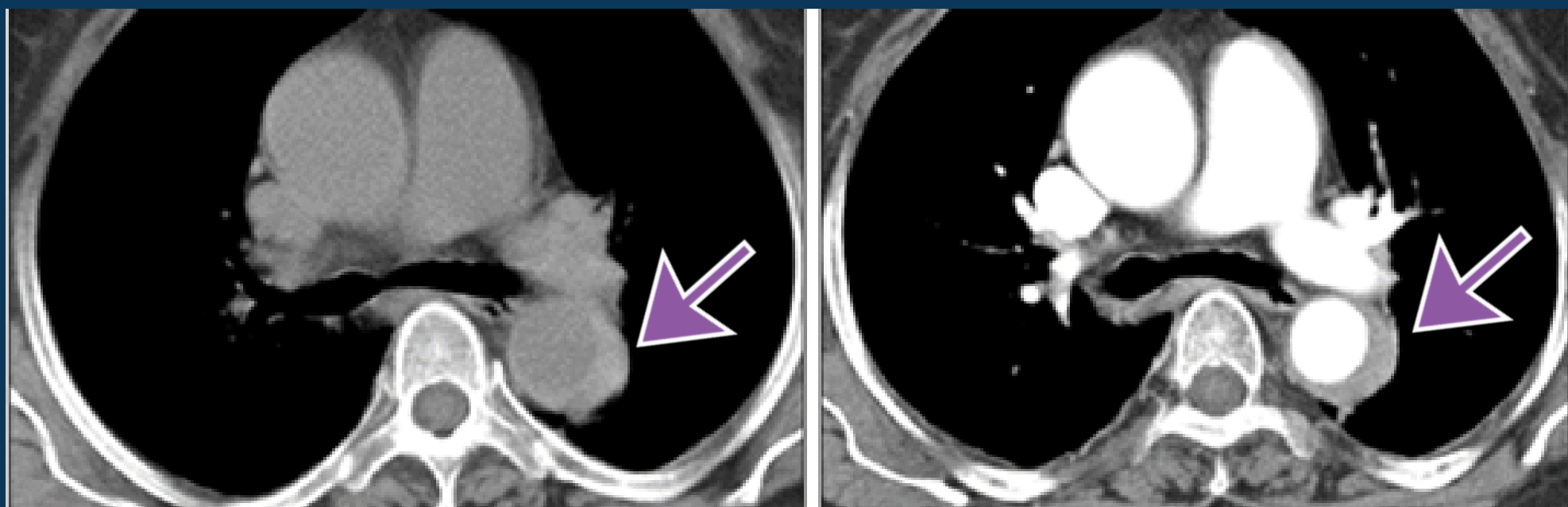
## Intramural Hematoma of the Aorta

CARDIOTHORACIC IMAGING NATIONAL SUBSPECIALTY DIVISION



### PEER LEARNING OPPORTUNITY

Acute aortic injury on noncontrast chest CT



*Increased mural density of the aorta can be a subtle finding, that may be hard to see on noncontrast exams.*



### PRACTICAL INSIGHTS

Given the serious nature of this injury, absent prior imaging, recommend contrast enhanced CTA if any suspected wall thickening, heterogeneity, increased density or displaced calcium of the aorta.



**DIRECT YOUR SEARCH TO THE AORTIC WALL EVEN IN NONCONTRAST EXAMS**

## CLINICAL VALUE