

Rad^{to}Rad Learning

Focused tips from our experts

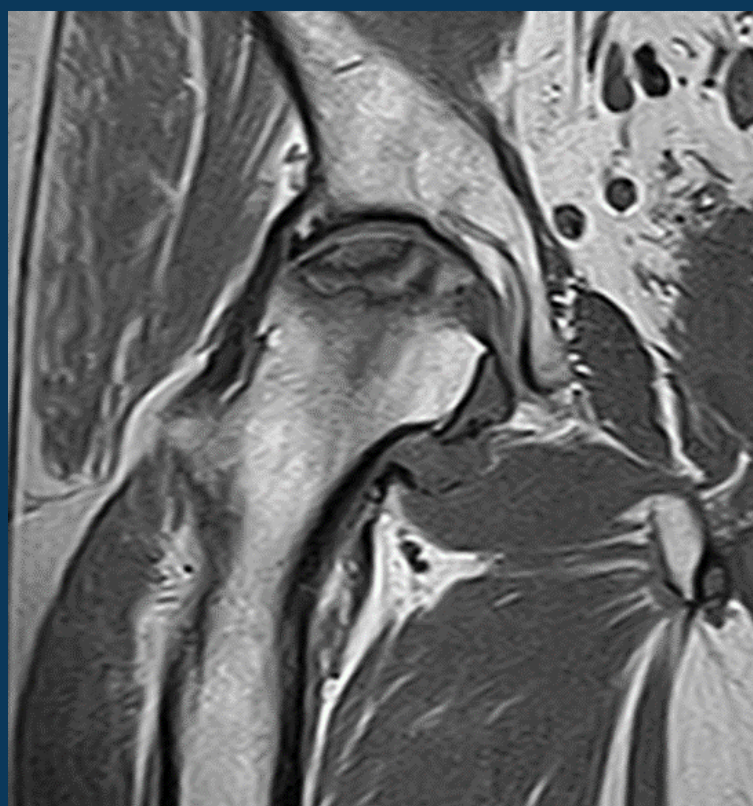
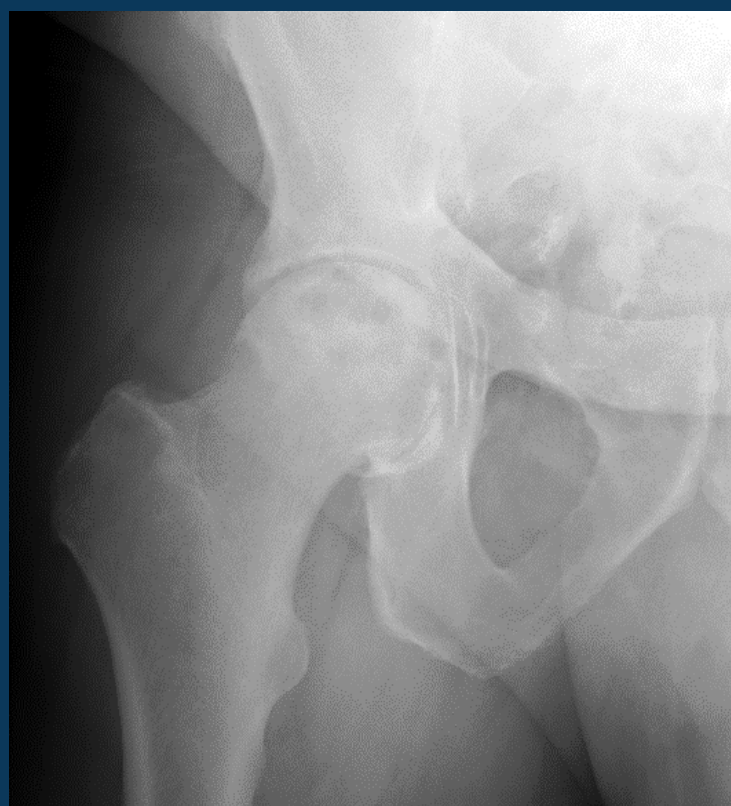
Osteonecrosis (AVN) of the Femoral Head

MSK NATIONAL SUBSPECIALTY DIVISION



PEER LEARNING OPPORTUNITY

Missed AVN can lead to end stage arthritis and hip replacement even in young patients.



Important to assess if bilateral.



PRACTICAL INSIGHTS

- Lack of collapse, arthritis or fracture are candidates for hip saving therapy.
- Can present as hip or groin pain and limited range of motion.
- Risk factors include high dose corticosteroid, trauma (hip dislocation), sickle cell disease, lupus, radiation, alcohol abuse and pancreatitis.



**ASYMPTOMATIC CONTRALATERAL HIP
CAN BECOME SYMPTOMATIC.**

CLINICAL VALUE